

Periodic Fever Syndromes

Shai Padeh, MD^{a,b,*}

^a*Pediatric Rheumatology, Edmond & Lily Safra Children Hospital, The Chaim Sheba Medical Center, Tel Hashomer 52621, Israel*

^b*Sackler School of Medicine, Tel-Aviv University, Tel Aviv, Israel*

The term auto-inflammatory disease has been proposed to describe a group of disorders characterized by attacks of seemingly unprovoked inflammation without significant levels of either autoantibodies or autoreactive T cells. The genetic causes of eight hereditary autoinflammatory syndromes have been identified in the last 7 years:

Familial Mediterranean fever (FMF)

Tumor necrosis factor (TNF) receptor-associated periodic syndrome (TRAPS)

Hyperimmunoglobulinemia D and periodic fever syndrome (HIDS)

Familial cold autoinflammatory syndrome (FCAS)/familial cold urticaria syndrome (FCUS)

Muckle-Wells syndrome (MWS)

Neonatal-onset multisystem inflammatory disease (NOMID)/chronic infantile neurologic cutaneous and articular (CINCA) syndrome

Blau syndrome

PAPA (Pyogenic sterile Arthritis, Pyoderma gangrenosum and Acne) syndrome

This article discusses those syndromes that are associated with recurrent fevers.

Members of a recently described family of genes, the pyrin family, account for several hereditary periodic fever syndromes. The study of autoinflammatory disease has progressed from clinical characterization to genetic analysis and to definition of the functional defects, linking pyrin genes or domains to apoptotic proteins and signal transduction pathways. As a result, the periodic fever syn-

* Pediatric Rheumatology, Edmond & Lily Safra Children Hospital, The Chaim Sheba Medical Center, Tel Hashomer 52621, Israel.

E-mail address: padeh@012.net.il

dromes have been associated with the field of innate immunology, and the classification of these disorders has been changed to autoimmune hereditary fevers. Most patients with hereditary periodic fevers have mutations in either the pyrin or the tumor-necrosis factor (TNF) receptor superfamily of molecules, both of which are intimately involved in innate immunity.

Both pyrin and a related gene, cryopyrin, contain an N-terminal domain that encodes a death domain-related structure, now known as the pyrin domain, or PyD. The PyD is a conserved sequence motif identified in more than 20 human proteins with putative functions in apoptotic and inflammatory signaling pathways [1]. Both pyrin and cryopyrin interact through their PyDs with a common adaptor protein, apoptotic speck protein (ASC). ASC itself participates in apoptosis, recruitment, and activation of pro-caspase-1 (with associated processing and secretion of interleukin [IL]-1 beta), and nuclear factor (NF)-kappa B,

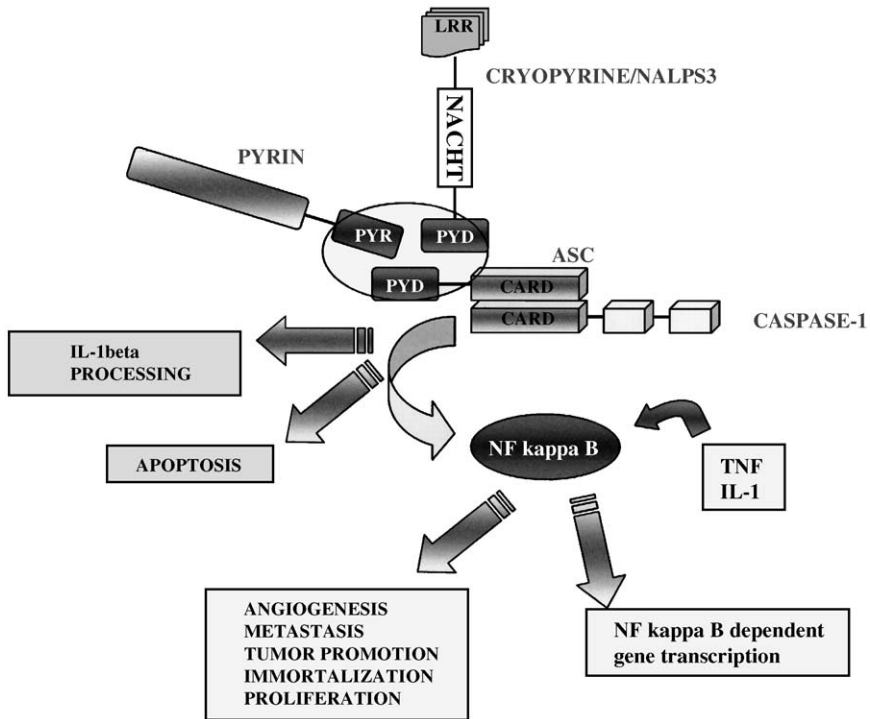


Fig. 1. Proteins containing PyD domain regulate inflammation through their interaction with apoptotic speck protein (ASC). The assembly of cryopyrin and ASC induces IL-1 processing through caspase-1, whereas pyrin may act as an inhibitor. Loss of function by mutations in the pyrin could potentially lead to autoinflammation by reducing the pyrin inhibitory role. Alternatively, gain-of-function mutations in cryopyrin, as found in MWS/FCU/NOMID patients, could activate this pathway. ASC participates in apoptosis and activation of NF-kappa B, a transcription factor involved in both initiation and resolution of the inflammatory response. IL-1, interleukin-1; LRR, LLR, leucine-rich repeats; TNF, tumor necrosis factor.

a transcription factor involved in both initiation and resolution of the inflammatory response (Fig. 1). Pyrin protein associates with tubulin and actin, leading to speculation that pyrin might regulate cytoskeletal organization in leukocytes. Hereditary pyrin mutants do not show altered cellular distribution and still colocalize with ASC. In contrast, cryopyrin displays granular cytoplasmic localization [2]. Expression of some PyD-containing proteins, including pyrin, and of ASC is controlled by interferons (IFNs). Inflammatory mediators such as lipopolysaccharide (LPS) and TNF increase the expression of cryopyrin, and its expression is also increased at sites of inflammation [2]. Likewise, pyrin is induced as an immediate early gene by proinflammatory molecules (eg, TNF, LPS, and IFNs), but inducibility is inhibited by anti-inflammatory cytokines (eg, IL-4, IL-10, and transforming growth factor-beta) [2]. In summary, pyrin and cryopyrin, through PyD:PyD interactions, seem to modulate the activity of apoptotic proteins and signal transduction pathways, playing a crucial role in the inflammatory pathways of the innate immune system [3–5].

Familial Mediterranean fever

FMF is an autosomal recessive disease mainly affecting ethnic groups living around the Mediterranean basin: Sephardic and Ashkenazi Jews, Armenians, Turks, Arabs, and Druze [6]. Scattered cases of FMF have been reported throughout the world, however, and cases are increasingly reported from other ethnicities, such as Greeks, Italians, Japanese, and others [7–9]. Although FMF existed in early Biblical times, it was first described as a separate nosologic entity in 1945 [10]. In the early 1950s, French investigators [11] described the disease in Jews of Sephardic extraction in North Africa and first reported nephropathy as part of the disease. In the same period, the disease was described in Armenian families [12]. Following the waves of emigration of Jews from North Africa, Iraq, and Turkey to the newly formed state of Israel in the 1950s, Sohar et al [13] and Heller et al [14] established a detailed clinical description of the condition. This description included recessive inheritance, arthritis, the nature of amyloid nephropathy, and the name familial Mediterranean fever. The benefit of prophylactic treatment with colchicine was first suggested by Goldfinger [15] and was later assessed by double-blind studies [16].

The gene responsible for FMF, *MEFV*, has been mapped to the short arm of chromosome 16 [17]. The protein encoded by this gene, termed pyrin/Marenostrin, is present almost exclusively in neutrophils and their precursors [18,19]. The role of pyrin is believed to decrease inflammation, specifically in neutrophils.

Clinical features

Painful febrile episodes constitute the hallmark of the disease. The febrile episodes are characterized by elevated temperatures of 38.5° to 40°C and in most

cases accompanied by signs of peritonitis, pleuritis, or acute synovitis, mainly of the knee, ankle, or hip. The attacks are short-lived, lasting for 1 to 3 days, and resolve without treatment. Between attacks, patients are perfectly well. Children commonly complain of headache and general malaise accompanying the elevated temperature. Recurrent oral aphthae are often reported, unassociated with attacks. Repeated attacks at irregular intervals and in an unpredicted sequence, rather than truly periodic attacks, are typical of the disease. The frequency of attacks may vary from once per week to periods of remissions of weeks or months with no apparent explanation. Over the course of the illness, a patient will probably experience several forms of attacks, but the recurrence of one type over many years is common [6]. In children, febrile attacks alone could be the first manifestation of the disease, occurring years before other forms of attacks appear. The age of onset in the cohort of 704 FMF patients followed in the Pediatric National Clinic in the Sheba Medical Center in Tel Hahsomer, Israel, is depicted in Fig. 2. About half of the cases had symptoms before the age of 4 years, and 80% had symptoms before the age of 10 years. The delay in diagnosis was in direct correlation to the age of patients at the onset, probably representing the difficulties in diagnosing very young patients (Fig. 3).

Abdominal attacks

Other than fever, the most frequent manifestation of FMF is the abdominal attack, experienced by 90% of patients. This attack is marked by the sudden onset of fever and generalized abdominal pain, guarding of the abdominal muscles, rebound tenderness, and abdominal distention, mimicking acute appendicitis. After 6 to 20 hours, the signs and symptoms recede, and within 24 to 48 hours the attack is usually over [6]. Often vomiting or diarrhea accompanies the abdominal pain. Many patients note that diarrhea terminates the attack. In severe cases, analgesics or intravenous rehydration is required. Organization of the exudate,

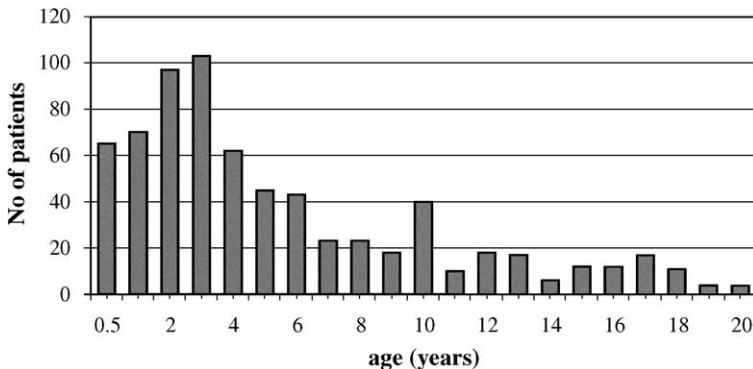


Fig. 2. The age at onset in a cohort of 704 FMF patients followed in the Pediatric National Clinic in the Sheba Medical Center in Tel Hahsomer, Israel.

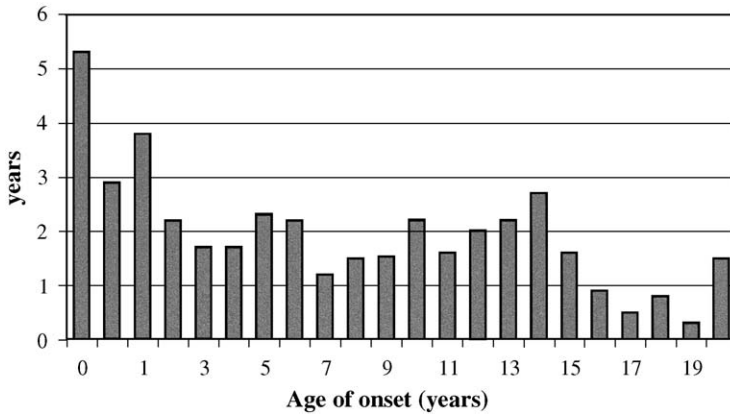


Fig. 3. The delay in diagnosis in a cohort of 704 FMF patients followed in the Pediatric National Clinic in the Sheba Medical Center in Tel Hahsomar, Israel.

which is formed in the peritoneum during the acute inflammation, may result in fibrous adhesions that in rare cases may give rise to mechanical ileus [20]. The adhesions are probably the cause of sterility in some women affected by FMF [21]. In the author's cohort of pediatric FMF patients, 65 (9%) underwent emergent appendectomy, but only 35 patients (5%) had acute appendicitis. Prophylactic appendectomy is not recommended, because in most cases both children and their parents can clearly distinguish between an abdominal attack of FMF and abdominal pain from other causes.

Acute scrotum

In males, inflammation of the tunica vaginalis testis may mimic episodes of torsion of the testis. Unilateral, erythematous, and tender swelling of the scrotum occurs in scrotal attacks. Fever and pain are present in all cases. The episodes are self-limiting and last from a few hours to 4 days [22].

Pleural attacks

Pleural attacks occur in 15% to 30% of patients [23]. Attacks present an acute one-sided febrile pleuritis resembling the peritoneal attacks in their abrupt onset, unpredictable recurrence, and rapid resolution. Breathing is painful, and breath sounds may be diminished in severe cases. There may be radiologic evidence of a small pleural effusion or mild pleural thickening.

Pericarditis attacks

Pericarditis is a rare feature of FMF. The author and colleagues observed clinical attacks of pericarditis in only six children with FMF (0.8%) [24]. This

type of attack also resolves within 1 to 3 days. Four of the children also had other forms of FMF attacks, but two had only pericarditis.

Articular attacks

Articular involvement is the second-most common form of FMF. The acute arthritis of FMF is abrupt and accompanied by high fever in the first 24 hours. In most cases, it is monoarticular and affects one of the large joints of the lower extremities (ie, the ankle, knee, or hip, in that order). The arthritis lasts longer than other FMF manifestations, usually peaking within 24 to 48 hours and then gradually subsiding, leaving no residua. Attacks often are precipitated by minor trauma or effort, such as prolonged walking. The arthritis of FMF differs significantly from juvenile idiopathic arthritis in many respects: the affected joint is hot, tender, and often red, resembling septic arthritis. The synovial fluid is sterile, but varies in appearance from cloudy to purulent and contains large numbers of neutrophils [6,14]. Nonsteroidal anti-inflammatory drugs (NSAIDs) are generally effective in FMF arthritis, and naproxen is used successfully during the attack. Rarely, FMF patients experience protracted arthritic attacks that may persist for more than a month (reported in 6% of adult patients [25]). These attacks usually occur in the hip or knee. Although not described in children, joint damage (mostly in the hip) can be severe and cause permanent deformity that may require joint replacement in some adult cases [25,26].

Myalgia

Muscle pain occurs in about 10% of children with FMF. The pain is usually mild, occurs mainly in the lower extremities after physical exertion or prolonged standing, lasts a few hours to 1 day, and subsides with rest or NSAIDs. In 1994 Langevitz et al [27] first described FMF patients with a syndrome of protracted febrile myalgia. This syndrome is characterized by severe debilitating myalgia, prolonged fever, abdominal pain without peritoneal irritation, a higher sedimentation rate than commonly found in FMF (around 100 mm in the first hour), leukocytosis, and hyperglobulinemia. In patients treated with NSAIDs the attacks lasted for 6 to 8 weeks but subsided promptly after treatment with prednisone, 1 mg/kg [27]. Because on rare occasions colchicine can induce neuropathy, it is important to differentiate colchicine-induced myopathy from protracted febrile myalgia.

Skin manifestations

Attacks of erysipelas-like erythema (ELE) (Fig. 4) are characteristic of FMF and sometimes are combined with arthritis. ELE occurred in 28.3% of the author's cohort of 704 pediatric FMF patients. Tender, hot, swollen, sharply bordered red lesions appear on the skin of the lower extremities. Usually located

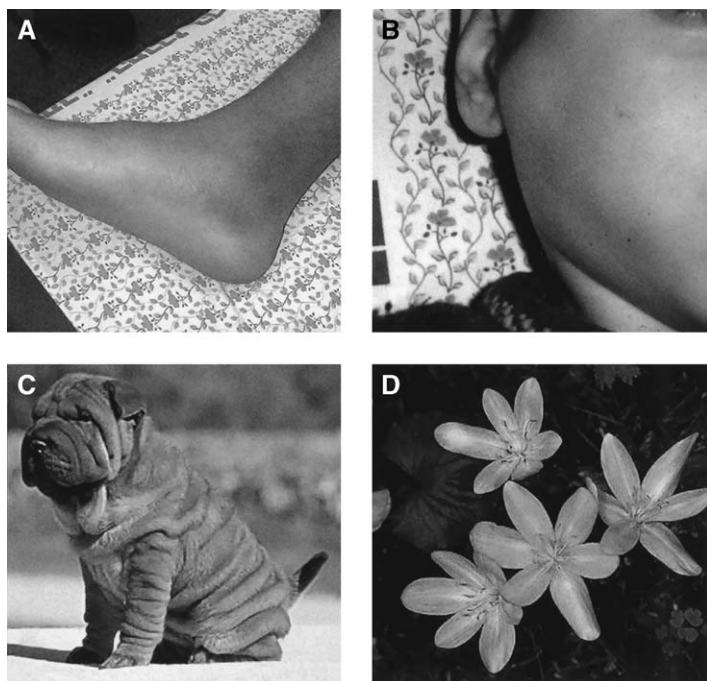


Fig. 4. (A) Erysipelas-like erythema of FMF and arthritis of the ankle. (B) Temporomandibular arthritis in FMF. (C) Familial Shar-Pei fever is a periodic disease occurring in Shar-Pei dogs. Clinically, the disease resembles FMF: febrile attacks are accompanied by arthritis, peritonitis, pleuritis, and amyloidosis. The *MEFV* gene is not found in the dog. (D) *Colchicum autumnale*, the flower from which colchicine is made.

between the knee and ankle, on the dorsum of the foot, or in ankle region, the dermatitis is often accompanied by abrupt elevation of body temperature and lasts 24 to 48 hours [6,28]. An erroneous diagnosis of cellulitis is often made and an antibiotic prescribed. Histologic examination of the lesions reveals edema of the superficial dermis and sparse perivascular infiltrate without vasculitis. In all cases, direct immunofluorescence shows deposits of C3 in the wall of the small vessels of the superficial vascular plexus [29].

Isolated febrile attacks

Isolated, short-lived elevation of temperature to 40°C without pain or signs of localized inflammation occurs mainly in young children and lasts a few hours. This phenomenon of FMF is often attributed falsely to viral infection [6]. The result is a delay in diagnosis and initiation of prophylactic colchicine therapy. In the author's cohort, in 50 children who first exhibited fever as the only

manifestation of FMF, other manifestations of FMF developed 4.5 ± 2.2 years after the onset of fevers (unpublished data). Once additional forms of attacks are present, the fever-only attacks subside, and the recognized pattern of FMF disease continues.

Vasculitis in familial Mediterranean fever

Vasculitides are found in FMF patients at a higher incidence than in the unaffected population. Henoch-Schonlein purpura (HSP) have been reported in 3% to 11% of FMF patients [6,30,31]. Occult FMF cases were identified in a series of children with HSP from Israel. Polyarteritis nodosa (PAN) also occurs more commonly in patients with FMF [32], with a younger age of onset [32]. Although abdominal pain and fever occur in both FMF attacks and PAN, hypertension, nephritis, and the persistence of symptoms are more likely to occur in PAN. Hematuria, sometimes only microscopic, has been observed in some patients during and between attacks of FMF.

Various types of glomerulonephritis have also been reported in FMF [33], but data are insufficient to determine whether these disorders are more common in FMF patients than in the general population. In the author's pediatric cohort, two patients had poststreptococcal glomerulonephritis, and five had Berger nephropathy. Transient microscopic hematuria is a common finding.

Amyloidosis of familial Mediterranean fever

Amyloidosis occurs frequently in untreated patients with FMF, and is of the AA type. It usually presents in FMF patients with persistent heavy proteinuria leading to nephrotic syndrome. The prevalence of amyloidosis in children in the colchicine era is unknown. In the cohort of 704 children seen by the author and colleagues, only 1 child developed end-stage renal disease, probably as a result of poor compliance with colchicine treatment. Amyloidosis is more common in other populations, however, and amyloidosis of different magnitude has been reported in children in Turkey [34]. Amyloid nephropathy has been reported in a child as young as 5 years of age [34]. In a study of 425 Turkish children with FMF from a registry of 20 years in a main referral center, 180 children developed amyloidosis. In the presence of a family history of amyloidosis plus consanguinity in FMF, patients had a 6.04-fold increased risk of amyloidosis [23].

Laboratory investigation

In all forms of attack, leukocytosis and elevated acute-phase reactants, including an accelerated erythrocyte sedimentation rate (ESR) and elevated levels of

C-reactive protein (CRP), fibrinogen, haptoglobin, C3, C4, and serum amyloid A are characteristic. Markers of inflammation often distinguish FMF attacks from common viral illnesses, functional abdominal pain, and irritable bowel syndrome. According to the reports of Gillmore et al [35], the increase in CRP was found to correlate better with FMF attacks, with levels much higher than in other inflammatory conditions. The mean ESR levels found during the attacks in the author's cohort of pediatric FMF patients was 52 ± 25 mm for the first hour. A very prolonged ESR (80–120 mm for the first hour) was indicative, in many cases, of other causes such as pneumonia or vasculitis. Proteinuria, as an indication of amyloidosis, will develop over the years if FMF is not treated. A yearly urinalysis to detect microalbuminuria is recommended in all patients.

Diagnosis and differential diagnosis

Until 1998, the diagnosis of FMF was based on clinical grounds alone. The presence of short-lived febrile episodes accompanied by inflammation of one of the serous membranes, the development of nephropathic amyloidosis, and the response to colchicine treatment were the grounds for the diagnosis. The ethnic origin of the patients and a family history of FMF may help direct the physician to a correct diagnosis but are not crucial for establishing a diagnosis of FMF. The most common differential diagnosis of FMF is functional abdominal pain, irritable bowel syndrome, and recurrent (intercurrent) infections in young children, and these symptoms are responsible for most referrals to FMF centers. The differential diagnosis includes diseases characterized by recurrent fever, such as hyper-IgD immunoglobulinemia (HIDS), TRAPS, and the periodic fever, adenopathy, pharyngitis, aphthae (PFAPA) syndrome.

Treatment

Until 1973, the treatment of FMF was restricted to alleviating pain. Daily prophylactic treatment with colchicine was suggested by Goldfinger [15] and assessed by double-blind studies [16]. Treatment is started with 1 mg colchicine per day (or 1.2 mg in the United States, where tablets of 0.6 mg are available), regardless of age or body weight. This dose is increased to 1.5 or 2 mg until remission is achieved. Doses higher than 1.5 mg must be divided and given twice a day. Some authors recommended adjusting the doses according to body weight or surface area. In one study, mean colchicine doses according to the body weight and surface area were 0.03 ± 0.02 mg/kg/day and 1.16 ± 0.45 mg/m² /day, respectively. Children younger than 5 years of age needed colchicine doses as high as 0.07 mg/kg/day or 1.9 mg/m² /day. These dosages were approximately 2.5 to three times higher than the mean colchicine dose for persons aged 16 to 20 years [36]. Omission of only one daily dose may result in an attack. The author and colleagues found that 65% of FMF patients enjoy

complete remission of attacks if they adhere to the daily dose of colchicine. An additional 30% of patients experience partial remission, defined as a significant decrease in the frequency and severity of attacks. In 5% of treated patients, the attack rate remains unchanged [16]. Nevertheless, these patients are maintained on 2 mg colchicine per day to prevent amyloidosis. The author's experience showed that continuous prophylactic treatment with colchicine in FMF patients inhibits the development of nephropathic amyloidosis. None of the patients without proteinuria who began treatment and adhered to the treatment regime developed amyloidosis during the 30-year follow-up. Side effects of colchicine are rare and generally mild, with diarrhea and nausea being the most common. These side effects are controlled easily by diet and gastrointestinal antispasmodic medications [16]. The author and colleagues prescribe colchicine to children as young as 1 year (at a dose of 0.5 mg/day), increased to an adult dose at the age of 2 years and have seen no serious toxicity. Diarrhea is often more severe at this age. Colchicine induces significant lactose malabsorption in FMF patients, and this malabsorption is partially responsible for the gastrointestinal side effects of the drug. [37]. The safety of colchicine is even more convincing, as evidenced by its continuing use during pregnancy without any complications [21,38]. In patients who do not respond to colchicine, the use of intravenous colchicine or IFN- α should be considered [39,40].

Genetic analysis and pathophysiology

The MEFV gene

In 1992, the gene responsible for FMF, *MEFV*, was found to reside on the short arm of chromosome 16 [17]. Five years later, the *MEFV* gene locus was discovered [18,19]. The International FMF Consortium has named the protein pyrin, from the Greek word for fire and fever, whereas the French FMF Consortium prefers to call it marenostriin, which is Latin for "our sea." Pyrin plays a role in mitigating an inflammatory response [19,41]. To date, more than 40 missense mutations are noted in association with FMF. One specific mutation, *M694V*, has been implicated as a risk factor for amyloidosis.

Pyrin is found in large quantities in neutrophils and is released in response to inflammatory stimuli. Additionally, a recently discovered pyrin-like domain was found to exist at the amino-terminal of several proteins involved in cell-signaling pathways inherent to inflammation. The pyrin protein encoded by the *MEFV* gene belongs to a larger class of the PyD family and is involved in the NF-kappa B cell-signaling pathway. NF-kappa B is an important transcription factor involved in inflammation through induction of proinflammatory gene products. In individuals with the wild-type *MEFV* gene, pyrin serves a key role in regulating the intensity of the inflammatory response. In contrast, individuals with one or more missense mutations at the *MEFV* locus produce a pyrin protein with altered or absent function. Consequently, the ability to regulate the

inflammatory response is reduced, and the resultant dysregulated inflammatory response often exceeds physiologic parameters and is disproportionate to the insult that initially triggered the neutrophil activation [4,42–45]. The exclusive expression of *MEFV* in neutrophils supports the clinical observations that neutrophils accumulate in large numbers at sites of inflammation during FMF attacks.

The recent cloning of *MEFV* and its putative role in white blood cells suggest that the gene may provide an advantage over an infectious agent prevalent in the region. Failure to control inflammation might give heterozygotes an advantage in dealing with some infections and may have given rise to the proliferation of the mutated gene. On the other hand, it has been shown that other inflammatory diseases (such as multiple sclerosis) progress rapidly in patients carrying one mutated *MEFV* gene, particularly *M694V*, because of the increased inflammatory damage inflicted by autoimmune responses [46].

Genotype–phenotype correlation

The cloning of the FMF gene *MEFV* and the identification of the mutations causing the disease raised hopes for a more rapid and accurate diagnostic test for FMF [18]. Molecular diagnosis is still not sensitive enough, however, because it fails to confirm the diagnosis of FMF in a large number of patients with typical presentation, even after the entire gene has been sequenced. In an analysis of 216 children with FMF, the author and colleagues found one of the three common *MEFV* mutations in 56% of the studied alleles, but only 38% of the children had two mutated alleles [47]. In another center in Israel [48], molecular testing for the common mutations identified two mutations in 48 of 67 patients (71.6%) of Jewish and Arab extraction (46.3% were Arab children). Divergent results reported from different centers may stem from differences in patient population, patient selection for genetic testing, and diagnostic criteria. Nevertheless, a significant proportion of patients with a typical clinical presentation of FMF and a favorable response to colchicine had only one mutation or none. With respect to genotyping, comparable findings were reported in adults [49] and children [48,50], showing that patients homozygous for the *M694V* mutation had an earlier onset, a more severe course, more joint involvement [51], higher temperature during attacks, higher prevalence of pleuritis, splenomegaly, ELE [50], and amyloidosis [52,53]. Since the identification of the *MEFV* gene, 40 point mutations have been reported. Most laboratories providing routine genetic testing of FMF screen for at least the five most frequent mutations (*M694V*, *V726A*, *V680I*, *E148Q*, and *M694I*), because the other mutations were found in fewer than 1% of FMF alleles. Genetic analysis does add valuable information, supporting the clinical diagnosis and reassuring the patients of the necessity of lifelong colchicine prophylaxis. Because FMF carries a high risk for the development of amyloidosis, leading to chronic renal failure if untreated [6,16], colchicine treatment should not be withheld because of a nonsupportive mutation analysis. Individuals who meet the clinical criteria for FMF but who have only

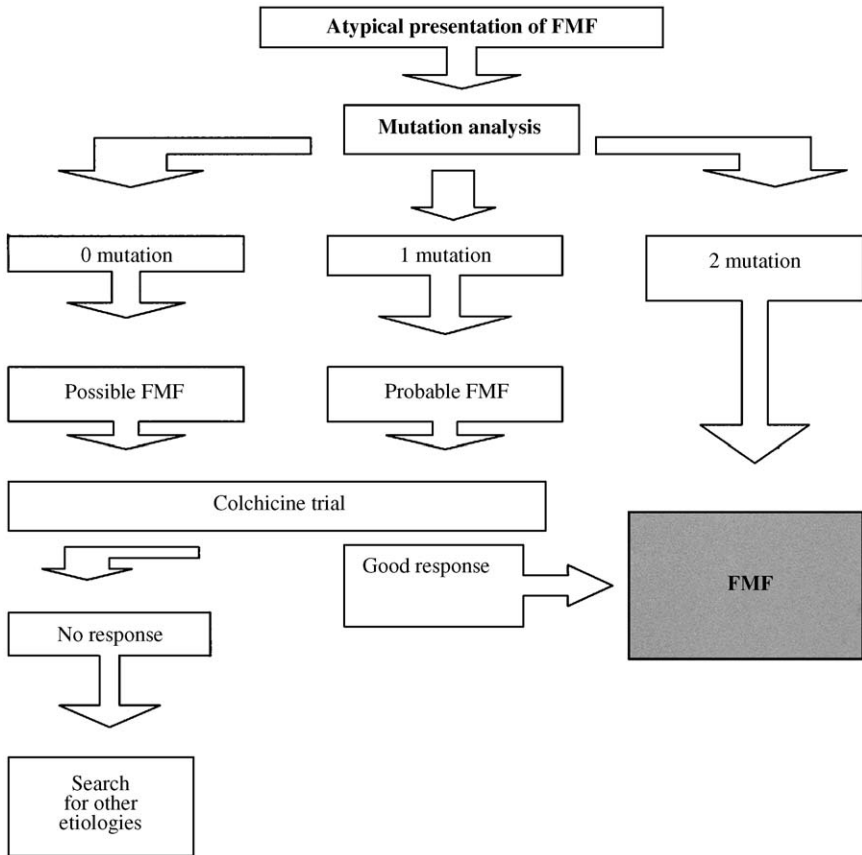


Fig. 5. An algorithm for the diagnosis of atypical clinical presentation of FMF. Patients with two mutations should be diagnosed with FMF and prescribed prophylactic colchicine therapy. Patients with one mutation should be considered as probably having FMF, and patients with no mutations should be considered as possibly having FMF. The last two groups of patients should undergo a colchicine trial consisting of 6 months of treatment followed by drug discontinuation. Those who have a favorable response are diagnosed as having FMF and should continue prophylactic colchicine treatment. Other causes for their symptomatology should be sought for those with no response.

one demonstrable mutation in the FMF gene may still harbor an unknown mutation (Fig. 5) [54,55].

Periodic fever accompanied by aphthous stomatitis, pharyngitis, and cervical adenitis syndrome

PFAPA syndrome is a chronic disease of unknown cause characterized by periodic episodes of high fever accompanied by aphthous stomatitis, pharyngitis,

and cervical adenitis, often associated with headache or abdominal or joint pain [56–58]. This syndrome belongs to the group of recurrent fever syndromes, which includes systemic-onset juvenile rheumatoid arthritis, cyclic neutropenia, and the group of hereditary fevers [59]. Unlike hereditary autoimmune fevers, however, PFAPA is a sporadic syndrome, and second cases in siblings are not found.

Clinical features

The earliest report of the syndrome was by Miller et al [60] who described 29 patients with febrile episodes occurring every 21.6 days for an average of 4.6 days. In 1987 Marshall et al [61] described a syndrome of periodic fever in 12 children, lasting 3 to 6 days and recurring every 3 to 8 weeks, accompanied by aphthous stomatitis, pharyngitis, and cervical adenitis. In 1989 they coined the acronym PFAPA to describe this entity [62]. They later described a larger series of 94 children identified with PFAPA and provided the long-term follow-up on 83 [56]. The author and colleagues have reported their experience with 28 cases [57]. PFAPA episodes last 4 to 5 days and resolve spontaneously. Attacks recur every 4 to 6 weeks, with temperatures up to 40.5°C. The affected children had no long-term sequelae. Episodes of fevers begin at the age of 4.2 ± 2.7 years. Fever, chills, sweats, headache, and muscle and bone pain are common. General malaise, resembling streptococcal pharyngitis, tonsillitis with negative throat cultures, and cervical adenopathy are typical of the syndrome. Less common are aphthae, abdominal pain, and arthralgia. Mild hepatosplenomegaly is observed in some patients. There is complete resolution between episodes; appetite and energy return to normal, and lost weight is regained. Affected children grew and developed normally, had no associated diseases, and experienced no long-term sequelae. The clinical presentation of patients with PFAPA in two large series [56,57] is summarized in Table 1. The differences between the two series probably derive from the differences in the diagnostic criteria of the two centers (Table 2). Except for the prevalence of aphthae, these figures have not changed in the current series of 220 children with PFAPA followed in the Sheba Medical Center.

Laboratory investigation

Laboratory investigation at onset of the fever showed a normal hemoglobin level, mild leukocytosis of $13 \times 10^9/\text{mm}^3$, moderate elevation of the ESR (41–56 mm for the first hour), and normal platelet count [56,57]. Serum IgD levels were elevated in 12 of the 18 patients (66%) in whom they were measured [57]. The levels were higher than 100 U/mL, which is the cut-off level for HIDS. The serum IgD levels (140.2 ± 62.4 U/mL) were significantly higher than those found in healthy children in an age-matched control group (16.5 ± 15.8 U/mL) or children with juvenile rheumatoid arthritis (85.9 ± 47.4 U/mL). Serum IgD levels were normal in the reports from Europe and the United States [56]. Immunologic

Table 1
Clinical presentation of patients with periodic fever, adenopathy, pharyngitis, aphthae syndrome

Symptom	Thomas et al (%)	Padeh et al (%)
Fever	100	100
Exudative tonsillitis	72 ^a	100
Malaise	NA	100
Cervical adenopathy	88	100
Aphthae	70	68
Headache	60	18
Abdominal pain	49	18
Arthralgia	79	11
Chills	80	NA
Cough	13	NA
Nausea	32	NA
Diarrhea	16	NA
Rash	9	NA

Abbreviations: NA, not available.

^a Pharyngitis rather than exudative tonsillitis.

Data from Thomas KT, Feder Jr HM, Lawton AR, et al. Periodic fever syndrome in children. *J Pediatr* 1999;135:15–21; Padeh S, Brezniak N, Zemer D, et al. Periodic fever, aphthous stomatitis, pharyngitis, and adenopathy syndrome: clinical characteristics and outcome. *J Pediatr* 1999;135:98–101.

and serologic studies were uniformly nondiagnostic [56]. Distributions of T-lymphocyte subsets were normal in all 12 patients studied [56]. IgE levels were elevated in 8 of 16 patients. Imaging studies included chest films, sinus films, gastrointestinal series, CT scans of the head and abdomen, gallium scans, and bone scans, all of which were negative [56].

Table 2
Differences in the diagnostic criteria of two centers for PFAPA syndrome

Thomas et al	Padeh
Regularly recurring fevers with an early age of onset (<5 years of age)	Monthly fevers – cyclic fever at any age groups
Constitutional symptoms in the absence of upper respiratory infection with at least 1 of the following clinical signs:	Possibly aphthous stomatitis Cervical lymphadenitis
Aphthous stomatitis	Exudative tonsillitis + negative throat culture
Cervical lymphadenitis	Completely asymptomatic interval between episodes
Pharyngitis	Rapid response to a single dose of corticosteroids
Exclusion of cyclic neutropenia	
Completely asymptomatic interval between episodes	
Normal growth and development	

Abbreviations: PFAPA, periodic fever, adenopathy, pharyngitis, aphthae syndrome.

Data from Thomas KT, Feder Jr HM, Lawton AR, et al. Periodic fever syndrome in children. *J Pediatr* 1999;135:15–21; Padeh S, Brezniak N, Zemer D, et al. Periodic fever, aphthous stomatitis, pharyngitis, and adenopathy syndrome: clinical characteristics and outcome. *J Pediatr* 1999;135:98–101.

Differential diagnosis

Periodic fever without other systemic manifestations or sites of disease has a short list of differential diagnoses. An infectious disease or malignancy is rarely diagnosed in an individual with predictable periodic fever [58,63]. Unexplained episodic fever can be the early manifestation that precedes frank Crohn's disease by months to years. Young age, normal growth, sustained sense of well-being, normal hemoglobin level, normal ESR between febrile episodes, and absence of recurring, even mild, pathologic signs or symptoms related to the bowel help distinguish patients with the PFAPA syndrome. Recurrent fever can be associated with congenital or acquired immunodeficiency disorders [64,65], such as deficiency of total immunoglobulins, IgG, or its subclasses; hyperimmunoglobulinemia M (mutations of CD40 ligand) [66] and E [67]; dysfunction/deficiency of T lymphocytes, phagocytic cells, or complement; cyclic neutropenia [68]; and HIV infection. Recurrent unusual or severe infections do not follow in PFAPA syndrome, however. Oral lesions are not distinctively different from the common, recurrent aphthous ulcers seen in individuals without systemic illness, although those ulcers tend to be singular or few, large, deep, and painful, and they frequently follow an identifiable insult. The prevalence of aphthae has dropped since the author and colleagues' first report of 28 patients and is now only 22% among the 220 patients with PFAPA followed in their clinic. Other manifestations of Behçet's disease, such as arthritis, genital ulcers, uveitis, erythema nodosum-like skin lesions, evidence of systemic vasculitis, and pathergy, are not seen in PFAPA patients. Systemic-onset juvenile idiopathic arthritis has hectic spiking fevers, generalized adenopathy, hepatosplenomegaly, and arthritis. Fever may persist for months without remission. Other than complicating infections and neutropenia, the clinical manifestations of cyclic neutropenia and PFAPA are remarkably similar. Although hereditary periodic fever syndromes share features of PFAPA, paroxysmal serosal or synovial inflammation is their dominant feature, with fever less consistent or cyclic. In HIDS, patients are predominantly (but not exclusively) of Dutch ancestry and have onset of fevers with predictable periodicity in infancy. Unlike PFAPA, abdominal symptoms, especially vomiting (56%) and diarrhea (82%), were dominant features in HIDS, and 80% of patients had polyarthralgia; aphthous stomatitis was not a manifestation [69]. Modestly elevated serum concentrations of IgD [57] and minimally to modestly elevated IgE levels [56] have been reported in PFAPA syndrome. Whether findings reflect normal variations in immunoglobulins, are results or markers of another abnormality, or represent one or more immunologic dysregulations as the cause of PFAPA syndrome remains unclear.

Treatment

Glucocorticoids are highly effective in controlling symptoms. Most of the patients given one dose of corticosteroid (2 mg/kg/day prednisone or

prednisolone or, preferably, 0.3 mg/kg of bethamethasone, which has a longer half-life), report a dramatic resolution of fever within 2 to 4 hours after the ingestion of the corticosteroid. In many cases, lower doses of corticosteroids successfully aborted the attacks, and the parents adjusted the doses individually. In addition, most of the associated symptoms resolved, with aphthous stomatitis being the slowest manifestation to respond. Although corticosteroid therapy did not prevent subsequent attacks, patients continued to respond on subsequent cycles. In the report by Thomas et al [56], some patients defervesced only after a longer course. As a starting point, they recommend a dose of 1 mg/kg prednisone or prednisolone at the beginning of an attack, the same dose on the next morning, and one half of that dose on days 3 and 4. Doses on days 3 and 4 may be omitted in some patients, as determined by trial during subsequent episodes. The author and colleagues usually instruct the patient's parents to administer the medication at the onset of the attack and consult the pediatrician only if the attack does not abort. In many patients, the cycles of fever became more closely spaced after initiation of glucocorticoid treatment, a phenomenon that is worrisome to the parents but always abates with time. The syndrome completely resolves over a period of 8 ± 2.5 years. In the Sheba Medical Center, attacks in most of the patients stopped before the age of 10 years. Two therapies reported to be effective in some patients are cimetidine [56,70] and tonsillectomy, with or without adenoidectomy. Tonsillectomy had been previously associated with resolution of PFAPA recurrences [71]. In the Sheba Medical Center, 12 patients underwent tonsillectomy. Histology and electron microscopy of the specimens were unrevealing, and deep cultures were negative. Attacks continued in patients (a 25% failure rate), and therefore the author and colleagues do not currently recommend tonsillectomy.

Pathophysiology

The cause of PFAPA is unknown. One potential clue is the remarkable similarity of uncomplicated episodes of cyclic neutropenia and febrile attacks in PFAPA [72]. Cyclic neutropenia is caused by an unidentified defect in hematopoietic precursor cells [73] or by alterations in the regulation of cytokines [74]. Mutations of the gene *ELA2* encoding neutrophil elastase cause a perturbed interaction between neutrophil elastase and serpins or other substrates that regulate the clocklike timing of hematopoiesis [75].

Perhaps PFAPA and cyclic neutropenia share common pathways of immune dysregulation. The ability of a single dose of corticosteroid to abort attacks of PFAPA suggests that the symptoms may be caused by inflammatory cytokines rather than by infection. Preliminary studies of cytokines in patients with PFAPA indicate that several cytokines are elevated during febrile episodes, most notably γ -IFN, TNF, and IL-6 [56]. It seems that an abnormal host immune response to yet unidentified commensally microorganisms in the tonsils or the oral mucosae may account for the symptomatology. Long [76] has hypothesized that

the periodicity of the PFAPA syndrome derives from intermittent expression or suppression of antigens or epitopes of infectious agents or an alteration in the nature or kinetics of immunologic response. Lack of second cases in siblings or other close contacts, lack of seasonal or geographic clustering, and the progression-free duration of PFAPA for years weigh heavily against an infectious disease.

Tumor necrosis factor receptor–associated periodic syndrome

TRAPS, formerly known as familial Hibernian fever (FHF), was first described in 1982 as an autosomal dominant periodic disease characterized by recurrent attacks of fever, abdominal pain, localized tender skin lesions, and myalgia in persons of Irish-Scottish ancestry. Pleurisy, leukocytosis, and high ESR were other features. The disease has a benign course, but later, secondary amyloidosis has been reported [77]. In patients with FHF, McDermott et al [78] identified germline mutations in the *TNFRSF1A* gene, which had been identified as a candidate gene by linkage studies [78]. The type 1 receptor (the *p55* TNF receptor) is encoded by a gene located on chromosome 12p13.2. [79] Twenty mutations have been identified since the initial discovery of the mutations in TNF receptor superfamily 1A (*TNFRSF1A*). Although originally found in patients of Irish or Scottish ancestry, mutations have been reported from diverse ethnicities, suggesting that the diagnosis of TRAPS should not be excluded based on a patient's ancestry [80].

Clinical features

The median age of onset is 3 years (range, 2 weeks to 53 years). Attacks last 21 days on average and occur every 5 to 6 weeks; however, this occurrence is extremely variable. Attacks are commonly described as beginning with the subtle onset of deep muscle cramping that crescendos over the course of 1 to 3 days and climaxes for a minimum of 3 days but frequently lasts longer. No definite stimulus is recognized, but several patients note that physical or emotional stress or physical trauma may trigger an attack. Fever is invariably seen in pediatric patients but may be absent during some attacks in adults. The temperature is higher than 38°C (maximally 41°C), lasts longer than 3 days, and generally heralds the onset of other inflammatory symptoms. Myalgia, typically affecting only a single area of the body and waxing and waning throughout the course of the attack, is nearly always present in TRAPS. Areas over the involved muscles are warm and tender to palpation. Myalgia migrates centrifugally over the course of several days. When myalgia involves a joint, there is often evidence of synovitis and effusion, as well as transient contracture of the affected limb. Serum creatine kinase and aldolase concentrations are within normal limits. Muscle biopsies suggest that the myalgia of TRAPS results from monocytic

fasciitis, not from myositis [81]. The most common and distinctive cutaneous manifestation is a centrifugal, migratory, erythematous patch, most typically overlying a local area of myalgia. These lesions are tender to palpation, warm, and blanch with pressure. They range in size from 1 to 28 cm. Although most occur in a single location, they may occasionally involve two separate areas. Skin biopsy reveals both a superficial and a deep perivascular and interstitial infiltrate of lymphocytes and monocytes without evidence of granuloma formation, vasculitis, or mast cell or eosinophilic infiltration [81]. Other, less distinct rashes, including urticaria-like plaques and generalized erythematous serpiginous patches and plaques, are also commonly observed. Abdominal pain occurs in 92% of TRAPS patients and may reflect inflammation within the peritoneal cavity or the musculature of the abdominal wall. Vomiting and constipation, with or without bowel obstruction, are common. Signs of an acute abdomen often result in laparotomy and appendectomy. In the series reported by Hull et al, 45% of patients had intra-abdominal surgery for acute abdominal pain, and 10% had later presented with necrotic bowel [81]. Eighty-two percent of patients presented with conjunctivitis, periorbital edema, or periorbital pain as a frequent manifestation of their attacks. Chest pain may be either musculoskeletal or pleural in origin and is present in 57% of patients. Testicular and scrotal pain has been reported during attacks. Prominent lymphadenopathy is not a universal feature of TRAPS; when observed, it is generally limited to a single anatomic location.

Laboratory investigation

All laboratory investigations measuring the acute-phase response show abnormalities during an attack including elevation of the ESR, CRP, haptoglobin, fibrinogen, and ferritin. Most patients demonstrate a polyclonal gammopathy that probably reflects IL-6-induced immunoglobulin production during attacks. The acute-phase reactants are often elevated between attacks, although not as significantly as during the attacks.

Diagnosis and differential diagnosis

A wide variability in clinical presentation has been reported [81]. The diagnosis of TRAPS should be considered when

1. A combination of the inflammatory symptoms, as described previously, recurs in episodes lasting more than 5 days.
2. Myalgia is associated with an overlying erythematous rash that together display a centrifugal migratory pattern over the course of days and occur on the limbs or trunk.
3. There is ocular involvement with attacks.
4. Symptoms respond to glucocorticosteroids but not to colchicine.
5. Symptoms segregate in the patient's family in an autosomal dominant pattern.

Clinically, the differential diagnosis includes all other periodic fevers, and the final diagnosis relies on mutation analysis.

Treatment

NSAIDs have some beneficial effect in TRAPS, mostly in relieving symptoms of fever, but are generally unable to resolve musculoskeletal and abdominal symptoms. Unlike in FMF, glucocorticoids are able to decrease the severity of symptoms but do not alter the frequency of attacks. Prednisone, 1 mg/kg/day taken in a single dose in the morning and tapered over the course of 7 to 10 days as tolerated, is recommended. Colchicine, azathioprine, cyclosporine, thalidomide, cyclophosphamide, chlorambucil, intravenous immunoglobulin, dapsone, and methotrexate have been tried empirically but have not been found to be beneficial [80]. In a pilot study involving nine TRAPS patients with various mutations in *TNFRSF1A* treated with etanercept over 6 months, an overall 66% response rate (as determined by decreased number of attacks) was observed [80,81].

Mutation analysis and pathophysiology

There does not seem to be a distinct correlation between patients' genotypes and their phenotypic presentations, with two notable exceptions: patients with the *R92Q* mutation seem to have a more heterogeneous clinical presentation than do other TRAPS patients, and patients with *TNFRSF1A* mutations involving cysteine residues seem to be at a greater risk of developing life-threatening AA amyloidosis. When TNF binds to its membrane receptor, the TNFRSF1A, it triggers a three-dimensional conformational change in the extracellular domain, which then induces an intracellular signal. Once activated, the extracellular portion of the receptor sheds from the cell membrane, contributing to the pool of soluble receptors that may attenuate the inflammatory response by removing TNF from the circulation and thereby preventing its binding to the cell-bound receptors. In their original description of TRAPS, Hull et al [81] showed that TRAPS patients possess lower serum levels of soluble TNFRSF1A than seen in normal controls. They hypothesized that the *TNFRSF1A* mutations mediated their effect through decreased shedding of TNFRSF1A, thereby decreasing the amount of soluble receptor available to bind soluble TNF- α and quell the inflammatory response. Later data, however, suggested that defective receptor shedding does not account entirely for the pathophysiologic mechanism observed, and that other mechanisms most likely contribute [81]. Although it is not entirely clear how these mutations alter TNFRSF1A receptor signaling, it is clear that the result is an inflammatory phenotype. Amelioration of inflammation in TRAPS by the anti-TNF p75:fusion protein etanercept suggests that the inflammation is dependent on the presence of TNF ligand and not on constitutive signaling by the mutated receptor [80,81].

Hyper-IgD and periodic fever syndrome

HIDS is a syndrome characterized by periodic febrile attacks occurring every 4 to 8 weeks with an intense inflammatory reaction accompanied by lymphadenopathy, abdominal pain, diarrhea, joint pain, hepatosplenomegaly, and cutaneous signs. HIDS was originally described in six patients by Van der Meer [82] in 1984. Subsequently, reports of similar cases have come from United Kingdom, France, and, later, Italy [83–85]. In 1995, by consensus, the acronym of HIDS was selected to designate the hyper-IgD syndrome [86]. Mutations in the gene encoding the enzyme mevalonate kinase (*MVK*) are responsible for this syndrome. The gene is located at chromosome 12q24 and is subjected to autosomal recessive inheritance [87,88]. *MVK* deficit has also been reported in mevalonic aciduria, a rare inherited disorder that is characterized by developmental delay, failure to thrive, hypotonia, ataxia, myopathy, and cataracts and is a completely different disease [87].

The diagnosis of HIDS is based on clinical signs associated with an elevated serum concentration of IgD, low activity of mevalonate kinase, and *MVK* gene mutation analysis. In a large series of 50 patients described by Drenth and van der Meer [89] most patients originated from Europe, namely The Netherlands (28 cases, 56%), France (10 cases, 20%), and Italy (3 cases, 6%). One patient was from Japan.

Clinical features

Patients present at a very early age at onset (median, 0.5 years) and have a life-long persistence of periodic fever. The attacks generally recur every 4 to 6 weeks, but the intervals between attacks can vary substantially in an individual patient and from one patient to another. Febrile attacks continue throughout the patients' lives, although the frequency of attacks is highest in childhood and adolescence. Patients may be free of attacks for months or even years. Attacks can be provoked by vaccination, minor trauma, surgery, or stress [89]. Attacks feature high spiking fever, preceded by chills in 76% of patients. Lymphadenopathy (94% of patients), abdominal pain, (72%), vomiting (56%), diarrhea (82%), headache (52, and skin lesions (82%) are common manifestations of the syndrome. Polyarthralgia was noted in 80% of patients, and a nondestructive arthritis, mainly of the large joints (knee and ankle), was reported in 68% of patients. Serositis is rare, and amyloidosis has not been reported. A minority of patients report painful, aphthous ulcers in the mouth or vagina. After an attack, patients are free of symptoms, although skin and joint symptoms resolve slowly. As a rule, attacks of arthritis do not lead to joint destruction, but there are exceptions [69,82,83,86,89]. Erythematous macules are the most common cutaneous manifestation, followed by erythematous papules, urticarial lesions, and erythematous nodules. Skin biopsy usually shows mild features of vasculitis [89,90].

Laboratory investigation

During an attack, there is a brisk acute-phase response, with leukocytosis, high levels of CRP and serum amyloid A, and activation of the cytokine network. The serum IgD level is persistently elevated (> 100 U/mL) in all except very young patients (< 3 years old). In 82% of cases, the serum IgA is likewise elevated (≥ 2.6 g/L). IgD should be measured on two occasions at least 1 month apart but may be normal in very young patients. More than 80% of patients have high IgA levels in conjunction with high IgD levels. Mevalonate kinase is a key enzyme in the cholesterol metabolic pathway and follows 3-hydroxy-3-methylglutaryl-coenzyme A reductase. In classic HIDS, the activity of mevalonate kinase is reduced to 5% to 15% of normal; as a result, serum cholesterol levels are slightly reduced; urinary excretion of mevalonic acid is slightly elevated during attacks [69,82,83,86,89].

Diagnosis and differential diagnosis

The diagnosis is based on clinical signs associated with an elevated serum concentration of IgD, low activity of mevalonate kinase, and *MVK* gene mutation analysis. None of the other periodic syndromes shares all these features. FMF resembles HIDS in many aspects. Increased IgD levels were found in 13% patients with FMF, significantly lower than the prevalence reported for HIDS [91]. Lymphadenectomy, skin eruption, and symmetrical oligoarthritis are seen only in HIDS, whereas monoarthritis, peritonitis, and pleuritis are more characteristic of FMF and are the main clinical features distinguishing FMF from HIDS. Unlike FMF, colchicine has no preventive effect against febrile episodes in HIDS [91].

Treatment

No effective treatment is known, and many of medications have been tried with limited response [89]. Thalidomide had a limited effect in decreasing the acute-phase protein synthesis without an effect on the attack rate [92]. Simvastatin resulted in a drop in urinary mevalonic acid concentration in six patients and decreased the number of febrile days [93]. Favorable experience with etanercept for the treatment of HIDS in two patients has been reported recently [94].

Genetic analysis and pathophysiology

HIDS is an autosomal recessive disease, and most patients are compound heterozygotes for missense mutations in the *MVK* gene. One mutation, *V377I*, is present in more than 80% of patients; the other mutations are less frequent [87,4]. The *V377I* mutation results in a slight reduction of the stability of recombinant human mevalonate kinase protein and in the catalytic activity of the enzyme. Fewer than 1% of patients have a complete deficiency of, which is

associated with mevalonic aciduria, in which disease-associated mutations are mainly clustered within a specific region of the protein [87]. How a deficiency of mevalonate kinase is linked to an inflammatory periodic fever syndrome is not yet known. Mevalonate kinase, a product of *MVK*, catalyzes the conversion of mevalonate to 5-phosphomevalonic acid in the biosynthesis of cholesterol and nonsterol isoprenoid compounds. Decreased mevalonate kinase activity, which is aggravated by fever, leads to accumulation of its substrate, mevalonate. Some clinical features in patients with mevalonic aciduria may result directly from the accumulation of mevalonate. In one report, however, patients with mevalonic aciduria developed severe febrile attacks following treatment with lovastatin [94], despite an initial decrease of mevalonate levels in the serum and urine [95], and it is therefore less likely that increased production of mevalonate itself is directly involved in the pathogenesis of febrile attacks. Decreased *MVK* activity also leads to decreased production of the molecules involved in prenylation, which is the posttranslational modification of proteins with isoprenoids such as farnesyl or geranyl moieties. Impaired prenylation, particularly of proteins providing regulatory control over ligand-induced cellular activation, may lower the threshold for the production of proinflammatory cytokine. An increased IL-1 production by HIDS leukocytes was found in vitro [94], but a direct link between disrupted prenylation and cytokine production or febrile attacks has yet to be elucidated.

CIAS1-related autoinflammatory syndromes

The *CIAS1* (named for cold-induced autoinflammatory syndrome) gene, located on chromosome 1p44, encodes a pyrin-like protein, cryopyrin, expressed predominantly in peripheral blood leukocytes. *CIAS1*-related autoinflammatory syndromes (CRAS) are three different diseases caused by mutation in the *CIAS1* gene: CINCA syndrome (also known as NOMID/CINCA syndrome), FCUS, and MWS [59,96,97]. The first clinical signs of severe CRAS occur during childhood, sometimes presenting right after birth, and comprise urticaria, recurrent fever, severe joint inflammation, myalgia, chronic meningitis often resulting in generalized neurologic impairment, a progressive visual defect, conjunctivitis, sensorineural deafness later in life, and, in a few cases, amyloidosis. The severity is influenced only partly by the underlying mutation; unknown modifier genes and environmental factors are other possible influences. In 1999, FCAS and MWS were first linked to the *CIAS1* gene. The encoded protein, cryopyrin, is a member of the pyrin and NACHT domain-containing family of proteins, which contain three domains, a PyD, a specific nucleotide-binding fold (the NACHT domain), and several tandem copies of leucine-rich repeats. Heterozygous missense mutations in the *CIAS1* gene were found later in patients with the NOMID/CINCA syndrome [98]. Aksentijevich et al [97] increased the total number of known germline mutations in *CIAS1* to 20, explaining a spectrum of diseases ranging from FCUS to MWS to NOMID/CINCA syndrome. Dode et al

[59] identified identical CIAS1 mutations in families with MWS and in families with FCUS of different ethnic origins, thereby demonstrating that a single CIAS1 mutation may cause both syndromes and suggesting that modifier genes are involved in determining either an MWS or an FCUS phenotype. The finding of the mutations in asymptomatic individuals further emphasizes the importance of a modifier gene (or genes) in determining disease phenotype. No CIAS1 mutation has yet been identified in the N-terminal PyD of cryopyrin. This 90–amino acid motif also is found in pyrin encoded by the FMF gene. It has recently been shown that cryopyrin interacts with ASC, leading to NF-kappa B activation, and through this pathway CIAS1 mutations may have an anti-apoptotic effect. No nuclear localization signals were identified, and no clear transmembrane regions were found, suggesting that cryopyrin is a signaling protein involved in the regulation of apoptosis.

Neonatal-onset multisystem inflammatory disease/chronic infantile neurologic cutaneous and articular syndrome

The triad of cutaneous rash, chronic meningitis, and arthropathy characterizes CINCA syndrome, also known as NOMID syndrome. It was first described by Prieur and Griscelli [85] in 1981 and was known to the pediatric rheumatologists long before it was genetically associated with the hereditary autoimmune fever syndromes. It is a disease of chronic inflammation, often starting at birth, which lasts the entire lifetime. Long-term prognosis is poor, with progressive deafness, visual impairment, and worsening of the central nervous system manifestations in many, but not all, patients. Attempts at therapy have been disappointing [85,99,100], although recently there have been reports of success with the IL-1 receptor antagonist anakinra [101]. Twenty years after its first description, NOMID/CINCA syndrome was linked to mutations in the CIAS1 gene on chromosome 1q44 [98]. Approximately 100 cases have been identified worldwide [100]. The course of the disease is characterized by chronic inflammation with recurrent flares; no permanent remission has yet been reported. Progressive growth retardation is observed in most patients. Fever and rash are dominant symptoms. Lymphadenopathy and hepatosplenomegaly are often present during flares, but skin rash is persistent. Skin manifestations are observed in all cases, and in 75% of cases these manifestations are present at birth. The rash is nonpruritic migratory urticaria. It can be confused with a systemic juvenile idiopathic arthritis rash but is more pronounced, persisting for the life of the patient. Skin biopsies show normal epidermis, with mild inflammation and perivascular mononuclear infiltration in the dermis. Immunofluorescence studies show no immunoglobulins or complement deposits in the skin lesion. Central nervous system involvement is not always suspected during the first years. Headaches, seizures, transient episodes of hemiplegia, and spasticity of the legs are characteristic of the syndrome. Neurologic features reflect chronic aseptic meningitis with polymorphonuclear infiltration of the meninges.

Extensive evaluations for viral, fungal, or bacterial agents have been negative, and no immune deficiency has been documented. Intellectual development may remain normal, but in some patients a low IQ can occur with time. Skull anomalies include increased cranial volume, frontal bossing, and late closure of the anterior fontanelle. Brain imaging often reveals mild ventricular dilatation, prominent sulci, and increased extra-axial fluid spaces. Calcification of the falx and dura can be seen in the oldest patients, perhaps reflecting the chronic inflammation of the meninges [99,100]. Cranial morphology demonstrates a peculiar aspect consisting of overall enlargement and frontal bossing (Fig. 6). Eye involvement can lead to a progressive visual defect and to blindness in the most severely affected cases. Optic disc edema, pseudopapilledema, and optic atrophy are most common. Chronic anterior uveitis is seen in half of the cases, but neither synechia nor glaucoma is evident. Progressive perceptive deafness, in varying degrees, increase with age. Hoarseness is frequent. A saddle-nose deformity is frequent.

Musculoskeletal abnormalities are characteristic. Shortening of the hands and feet with clubbing of the fingers is seen; sometimes the palms and soles appear wrinkled. These common morphologic features create a sibling-like resemblance among patients from various geographic areas [100]. Joint symptoms vary from arthralgia with transient swelling to severe deforming arthropathy. In children with a severe arthropathy, the progression of the bony lesions can lead to sig-

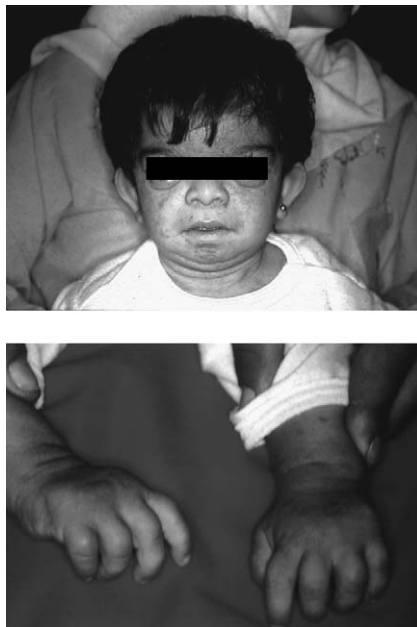

Fig. 6. A 3-year-old girl with NOMID/CINCA syndrome. Note the markedly deformed hands, rash, frontal bossing, and large head.

nificant deformity that impairs function. Symmetrical patellar overgrowth and epiphyseal and metaphyseal abnormalities often link with cartilage overgrowth, resulting in bony enlargement without synovial thickening. Joint effusions can occur, probably in association with a local, nonspecific reaction to the epiphyseal disturbances. A typical arthropathy with unique radiologic changes in the bones and joints is observed in about half of the cases. The most distinctive changes occur in the metaphyses and epiphyses at the ends of the long bones, affecting the knees, ankles, wrists, and elbows. Premature patellar ossification with subsequent patellar overgrowth is frequent. Epiphyses are large with irregular *en mie de pain* (“bread-crumbs”) ossification, often resulting in an overgrown and markedly deformed extremity. Growth plate histology shows a complete disorganization of the cartilage cell columns, irregular metachromasia of the cartilage substance, and no inflammatory cell infiltrates. The serum from affected patients is toxic to normal human growth cartilage cells in culture, suggesting that cartilage is a target in this disease. Hips, shoulders, and spine seem to be relatively unaffected [85,99,100].

Hypochromic anemia, leukocytosis with a predominance of polymorphonuclear neutrophils and eosinophils, high platelet counts, elevated ESR, and high levels of acute-phase reactants are often found. Secondary amyloidosis has been reported in some patients, probably as a consequence of chronic inflammation [99]. Leone et al [102] found a significantly increased expression of CD10 in some patients with NOMID/CINCA syndrome and postulated that it can serve as a useful marker of the inflammation in these patients.

Mutations in *CIAS1* have been found in only approximately 50% of the cases identified clinically as NOMID/CINCA syndrome, raising the possibility of genetic heterogeneity [97]. Because *CIAS1* is expressed in chondrocytes, genetic heterogeneity could explain the peculiar arthropathy of NOMID/CINCA syndrome. There were also substantial increases in IL-3 and IL-5 message, which may account for the peripheral eosinophilia observed in some patients with NOMID/CINCA syndrome. NOMID/CINCA syndrome *CIAS1* is also expressed at high levels in leukocytes, predominantly in monocytes, granulocytes, and T lymphocytes. In addition to the potential proinflammatory effect of alterations in NF-kappa B signaling in white blood cells, cryopyrin has recently been shown to regulate IL-1 beta production.

The differential diagnosis comprises other childhood febrile diseases, Kawasaki disease, infantile cortical hyperostosis (Caffey’s disease), Sweet’s syndrome, and Weber–Christian disease. Systemic-onset juvenile idiopathic arthritis shares many features with NOMID/CINCA syndrome but is rare in the first 6 months of life. The other hereditary autoinflammatory disorders associated with fever must be considered.

NSAIDs can relieve the pain but have no effect on the inflammatory features. Glucocorticosteroids reduce fever and pain without any effect on skin lesions, central nervous system disease, or joint manifestations. Attempts with more aggressive medications such as slow-acting anti-rheumatic drugs or cytotoxics have been disappointing [100]. Recently, favorable response to the recombinant

human IL-1 receptor antagonist anakinra has been reported in three patients [101]. Some cases of death have been reported secondary to infection, vasculitis, and amyloidosis [100].

Muckle–Wells syndrome

Urticaria-deafness-amyloidosis syndrome

In 1962, Muckle and Wells described a dominantly inherited syndrome of urticaria, progressive perceptive deafness, and amyloidosis. The first manifestations of MWS usually start during infancy and consist of nonpruritic urticaria, low-grade fever, and often arthritis and conjunctivitis. Neurosensory hearing loss begins during adolescence and slowly evolves into deafness. Absent organ of Corti, atrophy of the cochlear nerve, and amyloid infiltration of the kidneys have been found on autopsy. The severity of the disease resides in the development of AA amyloidosis [59]. Additional features reported to be associated with the syndrome are buccal and genital aphthosis, cystinuria and ichthyosis, polyarthralgia, periodic abdominal pain, and microscopic hematuria. The histologic findings of cold air-induced lesions are similar to those described for other different types of physical urticaria: marked dilatation of vessels and the dermal edema, intense infiltrate of neutrophils admixed with mononuclear cells and eosinophils, and sometime leukocytoclastic vasculitis or amyloid deposits in the skin. Recently, patients with MWS have been treated successfully with anakinra. [103]. Whether this treatment proves effective in preventing amyloidosis remains to be seen; at present, there is no effective treatment to prevent the attacks or the development of amyloidosis.

Familial cold autoinflammatory syndrome

FCAS, formerly known as familial cold urticaria, is a rare autosomal dominant syndrome characterized by fever, rash, and arthralgias brought on by exposure to cold. It was first reported in 1940; since then only 20 families have been described worldwide. This disorder is often confused with acquired cold urticaria (ACU). These are distinct and unrelated entities; FCAS is related more closely to the hereditary periodic fevers, and ACU is a true physical urticaria. Diagnostically, these two disorders are distinguished by their clinical history, by dermatologic examination, and by an ice cube challenge. After exposure to cold, the patient develops urticarial wheals, pain and swelling of joints, chills, and fever [104]. The onset of symptoms after cold challenge is delayed by 30 minutes to 6 hours. Urticaria is maximal in early adult life, but others have reported cases with onset in infancy [105]. Leukocytosis is common during an attack. Systemic amyloidosis is a complication of this condition, and amyloid nephropathy is a frequent cause of death. The clinical phenotype varies largely, and some patients never experience urticaria, induction of fever by cold, conjunctivitis, severe joint

Table 3
Summary of periodic fever syndromes

Disease	Inheritance	Gene location	Protein	Clinical presentation	Amyloidosis	Treatment
FMF	*AR	MEFV (16p13)	Pyrin	Recurrent attacks of fever and peritonitis, arthritis, pleuritis, pericarditis and erysipelas-like erythema	Yes	colchicine
PFAPA	sporadic	-		Periodic episodes of fever accompanied by aphthous stomatitis, pharyngitis, and cervical adenitis	No	glucocorticosteroids
TRAPS	AR	TNFRSF1A (12p13)	TNF receptor 1	Recurrent attacks of fever, conjunctivitis, abdominal pain, rash, myalgia, pleurisy, and arthritis.	Rarely	glucocorticosteroids, etanercept
HIDS	AR	MVK (12p24)	Mevalonate kinase	Periodic attacks of fever, lymphadenopathy, abdominal pains, vomiting, diarrhea, headache, and rash	No	No effective treatment (simvastatine, etanercept, thalidomide trials)
CINCA/NOMID	#AD	CIAS1 (1q44)	NALP3	Triad of cutaneous rash, chronic meningitis, and arthropathy. Fever, deforming arthritis, hepatosplenomegaly, and prolonged course.	Yes	glucocorticosteroids, MTX, etanercept, anakinra
MWS and FCUS	AD	CIAS1 (1q44)	NALP3	Fever, chills, rigors, malaise, urticaria (cold induced), progressive perceptible deafness, polyarthralgia, myalgia, periodic abdominal pain	Yes	anakinra, stanozolol

Abbreviations: AD, autosomal dominant; AR, autosomal recessive; CINCA, chronic infantile neurologic cutaneous and articular syndrome; FCUS, familial cold urticaria syndrome; FMF, familial Mediterranean fever; HIDS, Hyperimmunoglobulinemia D and periodic fever syndrome; MTX, methotrexate; MWS, Muckle-Wells syndrome; NOMID, neonatal-onset multisystem inflammatory disease; PFAPA, periodic fever, adenopathy, pharyngitis, aphthae) syndrome; TNF, Tumor necrosis factor; TRAPS, tumor necrosis factor receptor-associated periodic syndrome.

inflammation, neurologic symptoms, or amyloidosis. Instead, a very regular periodic fever, irregular severe febrile episodes, relatively mild arthralgia, dry cough, inflammatory cardiomyopathy and nephropathy, and euthyroid thyroiditis were observed [105]. Current management of patients with this syndrome consists of education, movement to warmer climates, and warming treatments. Anti-inflammatory agents, anabolic steroids, high-dose corticosteroids, and colchicine have variable effect in these patients. Antihistamines are generally not effective. Three patients responded favorably to treatment with stanazolol [106], and anakinra has also been reported to be effective [101].

Summary

Human autoinflammatory diseases (except for PFAPA) are a heterogeneous group of genetically determined diseases characterized by seemingly unprovoked inflammation, in the absence of autoimmune or infective causes (Table 3). The last decade has witnessed tremendous advances in the understanding of these disorders. These advances have allowed therapeutic interventions, resulting in improvement in the short-term and long-term morbidity of all of these diseases. Future research into the molecular mechanisms underlying these inflammatory diseases will probably lead to a better understanding of inflammatory diseases in general and, it is hoped, to better and more targeted therapies.

References

- [1] Kastner DL, O'Shea JJ. A fever gene comes in from the cold. *Nat Genet* 2001;29(3):241–2.
- [2] Stehlik C, Reed JC. The PYRIN connection: novel players in innate immunity and inflammation. *J Exp Med* 2004;200(5):551–8.
- [3] Liepinsh E, Barbals R, Dahl E, et al. The death-domain fold of the ASC PYRIN domain, presenting a basis for PYRIN/PYRIN recognition. *J Mol Biol* 2003;332(5):1155–63.
- [4] Manji G, Wang L, Geddes B, et al. PYPAF1, a PYRIN-containing Apaf1-like protein that assembles with ASC and regulates activation of NF-kappa B. *J Biol Chem* 2002;277:11570–5.
- [5] Miceli-Richard C, Lesage S, Rybojad M, et al. CARD15 mutations in Blau syndrome. *Nat Genet* 2001;29:19–20.
- [6] Sohar E, Gafhi J, Pras M, et al. Familial Mediterranean fever. A survey of 470 cases and review of the literature. *Am J Med* 1967;43:227–53.
- [7] La Regina MNG, Diaco M, Procopio A, et al. Familial Mediterranean fever is no longer a rare disease in Italy. *Eur J Hum Genet* 2004;12(2):85–6.
- [8] Konstantopoulos K, Kanta A, Deltas C, et al. Familial Mediterranean fever associated pyrin mutations in Greece. *Ann Rheum Dis* 2003;62(5):479–81.
- [9] Kotone-Miyahara Y, Takaori-Kondo A, Fukunaga K, et al. E148Q/M694I mutation in 3 Japanese patients with familial Mediterranean fever. *Int J Hematol* 2004;79(3):235–7.
- [10] Heller H, Sohar E, Kariv I, et al. Familial Mediterranean fever. *Harefuah* 1955;48:91–4.
- [11] Cattani R, Mamou H. 14 cas de Maladie periodique de dont 8 compliques de nephropathies. *Semaine Hop Paris* 1952;28:1062–70.
- [12] Retmann HA, Moadie J, Semerdjian S, et al. Periodic peritonitis—heredity and pathology. Report of seventy-two cases. *JAMA* 1954;154:1254–9.

- [13] Sohar E, Pras M, Heller J, et al. Genetics of familial Mediterranean fever. *Arch Intern Med* 1961;07:529–38.
- [14] Heller H, Gafni J, Michaeli D, et al. The arthritis of familial Mediterranean fever (FMF). *Arthritis Rheum* 1966;9:1–17.
- [15] Goldfinger SE. Colchicine for familial Mediterranean fever. *N Engl J Med* 1972;287(25):1302.
- [16] Zemer D, Revach M, Pras M, et al. A controlled trial of colchicine in preventing attacks of familial Mediterranean fever. *N Engl J Med* 1974;291:932–44.
- [17] Pras E, Aksentijevich I, Gruberg L, et al. Mapping of a gene causing familial Mediterranean fever to the short arm of chromosome 16. *N Engl J Med* 1992;326:1509–13.
- [18] The International FMF Consortium. Ancient missense mutations in a new member of the RoRet gene family are likely to cause familial Mediterranean fever. *Cell* 1997;90:797–807.
- [19] The French FMF Consortium. A candidate gene for familial Mediterranean fever. *Nat Genet* 1997;17:25–31.
- [20] Michaeli D, Pras M, Rozen N. Intestinal strangulation complicating familial Mediterranean fever. *BMJ* 1966;2:30–1.
- [21] Rabinovitch O, Zemer D, Kukia E, et al. Colchicine treatment in conception and pregnancy: two hundred thirty-one pregnancies in patients with familial Mediterranean fever. *Am J Reprod Immunol* 1992;28:245–6.
- [22] Majeed HA, Ghandour K, Shahin HM. The acute scrotum in Arab children with familial Mediterranean fever. *Pediatr Surg Int* 2000;16(1–2):72–4.
- [23] Saatci U, Ozen S, Ozdemir S, et al. Familial Mediterranean fever in children: report of a large series and discussion of the risk and prognostic factors of amyloidosis. *Eur J Pediatr* 1997; 156:619–23.
- [24] Kees S, Langevitz P, Zemer D, et al. Tel Aviv: pericarditis as a rare manifestation of familial Mediterranean fever (FMF). In: Sohar E, Gafni J, Pras M, editors. *Familial Mediterranean fever*. Tel Aviv, Israel: Freund Publishing House; 1997. p. 129–31.
- [25] Sneh E, Pras M, Michaeli D, et al. Protracted arthritis in familial Mediterranean fever. *Rheumatol Rehab* 1977;16:102–6.
- [26] Salai M, Langevitz P, Blankstein A, et al. Total hip replacement in familial Mediterranean fever. *Bull Hosp Jt Dis* 1993;53:25–8.
- [27] Langevitz P, Zemer D, Livneh A, et al. Protracted febrile myalgia in patients with familial Mediterranean fever. *Rheumatology* 1994;21:1708–9.
- [28] Azizi E, Fisher BK. Cutaneous manifestations of familial Mediterranean fever. *Arch Dermatol* 1976;1–2:364–6.
- [29] Barzilai A, Langevitz P, Goldberg I, et al. Erysipelas-like erythema of familial Mediterranean fever: clinicopathologic correlation. *J Am Acad Dermatol* 2000;42(5 Pt 1):791–5.
- [30] Pras E, Livneh A, Balow Jr JE, et al. Clinical differences between North African and Iraqi Jews with familial Mediterranean fever. *Am Med Genet* 1998;75:216–9.
- [31] Schlesinger M, Rubinow A, Vardy PA. Henoch-Schonlein purpura and familial Mediterranean fever. *Isr J Med Sci* 1985;21(1):83–5.
- [32] Sachs D, Langevitz P, Morag B, et al. Polyarteritis nodosa in familial Mediterranean fever. *Br J Rheumatol* 1987;26(2):139–41.
- [33] Said R, Hamzeh Y, Said S, et al. Spectrum of renal involvement in familial Mediterranean fever. *Kidney Int* 1992;41:414–9.
- [34] Oner A, Erdogan O, Demircin G, et al. Efficacy of colchicine therapy in amyloid nephropathy of familial Mediterranean fever. *Pediatr Nephrol* 2003;18(6):521–6.
- [35] Gillmore JD, Lovat LB, Persey MR, et al. Amyloid load and clinical outcome in AA amyloidosis in relation to circulating concentration of serum amyloid A protein. *Lancet* 2001; 358(9275):24–9.
- [36] Ozkaya N, Yalcinkaya F. Colchicine treatment in children with familial Mediterranean fever. *Clin Rheumatol* 2003;22:314–7.
- [37] Fradkin A, Yahav J, Zemer D, et al. Colchicine-induced lactose malabsorption in patients with familial Mediterranean fever. *Isr J Med Sci* 1995;31(10):616–20.

- [38] Ben-Chetrit E, Levy M. Reproductive system in familial Mediterranean fever: an overview. *Ann Rheum Dis* 2003;62(10):916–9.
- [39] Lidar M, Kedem R, Langevitz P, et al. Intravenous colchicine for treatment of patients with familial Mediterranean fever unresponsive to oral colchicine. *J Rheumatol* 2003;30(12):2620–3.
- [40] Tunca M, Tankurt E, Akbaylar Akpınar H, et al. The efficacy of interferon alpha on colchicine-resistant familial Mediterranean fever attacks: a pilot study. *Br J Rheumatol* 1997;36(9):1005–8.
- [41] Pras M. Familial Mediterranean fever: from clinical syndrome to the cloning of the Pyrin gene. *Scand J Rheumatol* 1998;27:92–7.
- [42] Guijarro C, Egido J. Transcription factor-kappa B (Nf-kappa B) and renal disease. *Kidney Int* 2001;59:415–24.
- [43] Ray A, Ray B. Persistent expression of serum amyloid A during experimentally induced chronic inflammatory condition in rabbit involves differential activation of SAF, Nf-kappa B, and C/EBP transcription factors. *J Immunol* 1999;163:2143–50.
- [44] Lawrence T, Gilroy GW, Colville-Nash PR, et al. Possible new role for NF-kappa B in the resolution of inflammation. *Nat Med* 2001;7:1291–7.
- [45] Livneh A, Langevitz P, Shinar Y, et al. MEFV mutation analysis in patients suffering from amyloidosis of familial Mediterranean fever. *Amyloid* 1999;6:1–6.
- [46] Shinar Y, Livneh A, Villa Y, et al. Common mutations in the familial Mediterranean fever gene associate with rapid progression to disability in non-Ashkenazi Jewish multiple sclerosis patients. *Genes Immun* 2003;4(3):197–203.
- [47] Padeh S, Shinar Y, Pras E, et al. Clinical and diagnostic value of genetic testing in 216 Israeli children with familial Mediterranean fever. *J Rheumatol* 2003;30(1):185–90.
- [48] Brik R, Riva MD, Shinaw M, et al. Familial Mediterranean fever: clinical and genetic characterization in a mixed pediatric population of Jewish and Arab patients. *Pediatrics* 1999;103(5):1025–6.
- [49] Shinar Y, Livneh A, Langevitz P, et al. Genotype-phenotype assessment of common genotypes among patients with familial Mediterranean fever. *J Rheumatol* 2000;27:1703–7.
- [50] Kone Paut I, Dubuc M, Sportouch J, et al. Phenotype-genotype correlation in 91 patients with familial Mediterranean fever reveals a high frequency of mucocutaneous features. *Rheumatology* 2000;39:1275–9.
- [51] Dewalle M, Domingo C, Rozenbaum M, et al. Phenotype-genotype correlation in Jewish patients suffering from familial Mediterranean fever. *Eur J Hum Genet* 1998;6:95–7.
- [52] Cazeneuve C, Sarkisian T, Pecheux C, et al. MEFV-gene analysis in Armenian patients with familial Mediterranean fever: diagnostic value and unfavorable renal prognosis of the M694V homozygous genotype—genetic and therapeutic implications. *Am J Hum Genet* 1999;65:88–97.
- [53] Shohat M, Magal N, Shohat T, et al. Phenotype-genotype correlation in familial Mediterranean fever: evidence for an association between Met694Val and amyloidosis. *Eur J Hum Genet* 1999;7:287–92.
- [54] Booth DR, Gillmore JD, Lachmann HJ, et al. The genetic basis of autosomal dominant familial Mediterranean fever. *Q J Med* 2000;93:217–21.
- [55] Livneh A, Aksentijevich I, Langevitz P, et al. A single mutated MEFV allele in Israeli patients suffering from familial Mediterranean fever and Behcet's disease (FMF-BD). *Eur J Hum Genet* 2001;9:191–6.
- [56] Thomas KT, Feder Jr HM, Lawton AR, et al. Periodic fever syndrome in children. *J Pediatr* 1999;135:15–21.
- [57] Padeh S, Brezniak N, Zemer D, et al. Periodic fever, aphthous stomatitis, pharyngitis, and adenopathy syndrome: clinical characteristics and outcome. *J Pediatr* 1999;135:98–101.
- [58] Knockaert DC, Vanneste LJ, Bobbaers HJ. Recurrent or episodic fever of unknown origin: review of 45 cases and survey of the literature. *Medicine (Baltimore)* 1993;72:184–96.
- [59] Dode C, Le Du N, Cuisset L, et al. New mutations of CIAS1 that are responsible for Muckle-

- Wells syndrome and familial cold urticaria: a novel mutation underlies both syndromes. *Am J Hum Genet* 2002;70:1498–506.
- [60] Miller LC, Sisson BA, Tucker LB, et al. Prolonged fevers of unknown origin in children: patterns of presentation and outcome. *J Pediatr* 1996;129:419–23.
- [61] Marshall GS, Edwards KM, Butler J, et al. Syndrome of periodic fever, pharyngitis, and aphthous stomatitis. *J Pediatr* 1987;110:43–6.
- [62] Marshall GS, Edwards KM. PFAPA syndrome [letter]. *Pediatr Infect Dis J* 1989;8:658–9.
- [63] Cabral DA, Tucker LB. Malignancies in children who initially present with rheumatic complaints. *J Pediatr* 1999;134(1):53–7.
- [64] Rosen FS, Cooper MD, Wedgewood RJP. The primary immunodeficiencies [medical progress]. *N Engl J Med* 1995;333:431–40.
- [65] Shyur S-D, Hill HR. Immunodeficiency in the 1990s. *Pediatr Infect Dis J* 1991;10:595–611.
- [66] DiSanto JP, Bonnefoy Y, Gauchat JF, et al. CD40 ligand mutations in X-linked immunodeficiency with hyper-IgM. *Nature* 1993;361:541–3.
- [67] Grimbacher B, Holland SM, Gallin JI, et al. Hyper-IgE syndrome with recurrent infections—an autosomal dominant multisystem disorder. *N Engl J Med* 1999;340:692–702.
- [68] Yang K, Hill HR. Assessment of neutrophil function disorders: practical and preventive interventions. *Pediatr Infect Dis J* 1994;13:906–19.
- [69] Grose C, Schnetzer JR, Ferrante A, et al. Children with hyperimmunoglobulinemia D and periodic fever syndrome. *Pediatr Infect Dis J* 1996;15(1):72–5.
- [70] Feder Jr HM. Cimetidine treatment for periodic fever associated with aphthous stomatitis, pharyngitis, and cervical adenitis. *Pediatr Infect Dis J* 1992;11:318–21.
- [71] Abramson JS, Givner LB, Thompson JN. Possible role of tonsillectomy and adenoidectomy in children with recurrent fever and tonsillopharyngitis. *Pediatr Infect Dis J* 1989;8:119–20.
- [72] Wright DG, Dale DC, Fauci AS, et al. Human cyclic neutropenia: clinical review and long-term follow-up of patients. *Medicine (Baltimore)* 1981;60:1–13.
- [73] Dale DC, Hammond WP. Cyclic neutropenia: a clinical review. *Blood Rev* 1988;2:178–85.
- [74] Engervall P, Andersson B, Bjorkholm M. Clinical significance of serum cytokine patterns during start of fever in patients with neutropenia. *Br J Haematol* 1995;91:838–45.
- [75] Horwitz M, Benson KF, Person RE, et al. Mutations in ELA2, encoding neutrophil elastase, define a 21-day biological clock in cyclic haematopoiesis. *Nat Genet* 1999;23(4):433–6.
- [76] Long SS. Syndrome of periodic fever, aphthous stomatitis, pharyngitis, and adenitis (PFAPA)—what it isn't. What is it? *J Pediatr* 1999;135(1):1–5.
- [77] Williamson LM, Hull D, Mehta R, et al. Familial Hibernian fever. *Q J Med* 1982;51:469–80.
- [78] McDermott MF, Aksentjevich I, Galon J, et al. Germline mutations in the extracellular domains of the 55 kDa TNF receptor, TNFR1, define a family of dominantly inherited autoinflammatory syndromes. *Cell* 1999;97:133–44.
- [79] Derre J, Kemper O, Cherif D, et al. The gene for the type 1 tumor necrosis factor receptor (TNF-R1) is localized on band 12p13. *Hum Genet* 1991;87:231–3.
- [80] Drewe E, Powell PT, Isaacs JD, et al. Prospective study of anti-tumor necrosis factor superfamily 1a and 1b fusion proteins in tumor necrosis factor associated periodic syndrome (TRAPS): clinical and laboratory findings in a series of six patients. *Rheumatology (Oxford)* 2003;42(2):235–9.
- [81] Hull KM, Drewe E, Aksentjevich I, et al. The TNF receptor-associated periodic syndrome (TRAPS): emerging concepts of an autoinflammatory disorder. *Medicine (Baltimore)* 2002; 81(5):349–68.
- [82] Van der Meer JWM, Vossen JM, Radl J, et al. Hyperimmunoglobulinemia D and periodic fever: a new syndrome. *Lancet* 1984;i:1087–90.
- [83] Reeves WG, Mitchell JRA. Hyperimmunoglobulinemia D and periodic fever. *Lancet* 1984;i: 1463–4.
- [84] Scolozzi R, Boccafogli A, Vicentini L. Hyper-IgD syndrome and other hereditary periodic fever syndromes. *Reumatismo* 2004;56(3):147–55.
- [85] Prieur AM, Griscelli C. Nosologic aspects of systemic forms of very early onset juvenile arthritis. Apropos of 17 cases. *Ann Pediatr (Paris)* 1983;30(8):565–9.

- [86] Drenth JPH, Powell RJ. Hyperimmunoglobulinemia D syndrome: conference. *Lancet* 1995; 345:445–6.
- [87] Drenth JP, Cuisset L, Grateau G, et al. Mutations in the gene encoding mevalonate kinase cause hyper-IgD and periodic fever syndrome. International Hyper-IgD Study Group. *Nat Genet* 1999;22:178–81.
- [88] McDermott M, Ogunkolade BW, McDermott EM, et al. Linkage of familial Hibernian fever to chromosome 12p13. *Am J Hum Genet* 1998;62:1446–51.
- [89] Drenth JP HC, van der Meer JW. Hyperimmunoglobulinemia D and periodic fever syndrome. The clinical spectrum in a series of 50 patients. International Hyper-IgD Study Group. *Medicine (Baltimore)* 1994;73(3):133–44.
- [90] Drenth JP, Boom BW, Toonstra J, et al. Cutaneous manifestations and histologic findings in the hyperimmunoglobulinemia D syndrome. International Hyper IgD Study Group. *Arch Dermatol* 1994;130(1):59–65.
- [91] Livneh A, Drenth JP, Klasen IS, et al. Familial Mediterranean fever and hyperimmunoglobulinemia D syndrome: two diseases with distinct clinical, serologic, and genetic features. *Rheumatology* 1997;24(8):1558–63.
- [92] Drenth JP, Vonk AG, Simon A, et al. Limited efficacy of thalidomide in the treatment of febrile attacks of the hyper-IgD and periodic fever syndrome: a randomized, double-blind, placebo-controlled trial. *J Pharmacol Exp Ther* 2001;298(3):1221–6.
- [93] Simon A, Drewe E, van der Meer JW, et al. Simvastatin treatment for inflammatory attacks of the hyperimmunoglobulinemia D and periodic fever syndrome. *Clin Pharmacol Ther* 2004; 75(5):476–83.
- [94] Takada K, Aksentjevich I, Mahadevan V, et al. Favorable preliminary experience with etanercept in two patients with the hyperimmunoglobulinemia D and periodic fever syndrome. *Arthritis Rheum* 2003;48(9):2645–51.
- [95] Hoffmann GF, Charpentier C, Mayatepek E, et al. Clinical and biochemical phenotype in 11 patients with mevalonic aciduria. *Pediatrics* 1993;91:915–21.
- [96] Hoffman H, Mueller J, Broide D, et al. Mutation of a new gene encoding a putative pyrin-like protein causes familial cold autoinflammatory syndrome and Muckle-Wells syndrome. *Nat Genet* 2001;29:301–5.
- [97] Aksentjevich I, Nowak M, Mallah M, et al. De novo CIAS1 mutations, cytokine activation, and evidence for genetic heterogeneity in patients with neonatal-onset multisystem inflammatory disease (NOMID): a new member of the expanding family of pyrin-associated auto-inflammatory diseases. *Arthritis Rheum* 2002;46(12):3340–8.
- [98] Feldmann J, Prieur A-M, Quartier P, et al. Chronic infantile neurological cutaneous and articular syndrome is caused by mutations in CIAS1, a gene highly expressed in polymorphonuclear cells and chondrocytes. *Am J Hum Genet* 2002;71:198–203.
- [99] Prieur AM, Griscelli C, Lambert F, et al. A chronic, infantile, neurological, cutaneous and articular (CINCA) syndrome. A specific entity analysed in 30 patients. *Scand J Rheumatol* 1987;66(Suppl):57–68.
- [100] Prieur AM. A recently recognised chronic inflammatory disease of early onset characterised by the triad of rash, central nervous system involvement and arthropathy. *Clin Exp Rheumatol* 2001;19(1):103–6.
- [101] Frenkel J, Wulfraat NM, Kuis W. Anakinra in mutation-negative NOMID/CINCA syndrome: comment on the articles by Hawkins et al and Hoffman and Patel. *Arthritis Rheum* 2004; 50(11):3738–9.
- [102] Leone V, Presani G, Perticarari S, et al. Chronic infantile neurological cutaneous articular syndrome: CD10 over-expression in neutrophils is a possible key to the pathogenesis of the disease. *Eur J Pediatr* 2003;162(10):669–73.
- [103] Hawkins PN, Lachmann HJ, Aganna E, et al. Spectrum of clinical features in Muckle-Wells syndrome and response to anakinra. *Arthritis Rheum* 2004;50(2):607–12.
- [104] Derbes VJ, Coleman WP. Familial cold urticaria. *Ann Allergy* 1972;30:335–41.
- [105] Porksen G, Lohse P, Rosen-Wolff A, et al. Periodic fever, mild arthralgias, and reversible

moderate and severe organ inflammation associated with the V198M mutation in the CIAS1 gene in three German patients—expanding phenotype of CIAS1 related autoinflammatory syndrome. *Eur J Haematol* 2004;73(2):123–7.

- [106] Ormerod AD, Smart L, Reid TMS, et al. Familial cold urticaria: investigation of a family and response to stanozolol. *Arch Dermatol* 1993;129:343–6.